

CLINICAL TECHNIQUES AND TECHNOLOGY

Vastus lateralis myofascial free flap in tongue reconstruction

Leombo miofasciale di vasto laterale nella ricostruzione della lingua

R. PELLINI¹, A. DE VIRGILIO^{1,2}, G. MERCANTE¹, B. PICHI¹, V. MANCIOCCO¹, P. MARCHESI¹, F. FERRELLI¹, G. SPRIANO¹

¹ Department of Otolaryngology-Head and Neck Surgery, Regina Elena National Cancer Institute, Rome, Italy;

² Department Organs of Sense, ENT Section, University of Rome "La Sapienza", Rome, Italy

SUMMARY

In the last decade, the antero-lateral thigh free flap (ALT) has become the most popular free flap for tongue reconstruction because of less donor site morbidity and better cosmetic outcomes. However, fascio-cutaneous ALT may be insufficient to reconstruct major tongue defects, while its muscular-cutaneous variant (using the vastus lateralis muscle) may be too bulky. The present study describes our preliminary experience of tongue reconstruction with vastus lateralis myofascial flap, which could potentially offer unique advantages in head and neck reconstruction including adequate bulk when needed, optimal functional results and obliteration of dead space thus preventing fistulas and infections with minimal morbidity.

KEY WORDS: Free flap • Glossectomy • Rectus femoris • Tongue reconstruction • Vastus lateralis

RIASSUNTO

Nell'ultimo decennio il lembo antero-laterale di coscia (ALT) è diventato il lembo libero più utilizzato nella ricostruzione della lingua, dal momento che esso è caratterizzato da bassa morbidity a livello del sito donatore e da migliori risultati estetici. Tuttavia, l'ALT fascio-cutaneo può essere insufficiente nella ricostruzione nei difetti maggiori (es. glossectomia totale) mentre la sua variante muscolo-cutanea (che include il muscolo vasto laterale) può essere troppo voluminosa. Scopo dello studio è quello di descrivere la nostra esperienza preliminare nella ricostruzione della lingua utilizzando il lembo libero mio-fasciale di vasto laterale che potrebbe a nostro parere offrire notevoli vantaggi nella ricostruzione testa-collo come: possibilità di confezionare un lembo voluminoso quando necessario, ottimi risultati funzionali, oblitterazione di spazi morti con prevenzione dello sviluppo di fistola e infezione con minima morbidity a livello del sito donatore.

PAROLE CHIAVE: Lembo libero • Glossectomia • Retto femorale • Ricostruzione della lingua • Vasto laterale

Acta Otorhinolaryngol Ital 2016;36:321-325

Introduction

Nowadays many free flaps have been described and successfully used in oral cavity reconstruction^{1,2}. In the last decade, the antero-lateral thigh free flap (ALT) became the most popular because of less donor site morbidity and better cosmetic outcomes². However, fascio-cutaneous ALT may be insufficient to reconstruct major tongue defects, while its muscular-cutaneous variant (using the vastus lateralis muscle) may be too bulky, especially in patients with a high body mass index (BMI).

The aim of our study was to describe surgical technique and analyze the feasibility of vastus lateralis myofascial free flap (VLMFF) in tongue reconstruction, which to our knowledge has not been reported in the current literature.

Clinical technique

The National Cancer Institute 'Regina Elena' of Rome

Ethics Committee approved the pilot study. Three patients affected by tongue squamous cell carcinoma (SCC) were treated from July to October 2015. All patients were staged with biopsy of the tumor, head and neck contrast MRI/CT and PET-CT. All patients underwent a temporary tracheostomy and nasogastric feeding tube placement. In Table I we summarised the patients' clinical data. Reconstructions were performed by VLMFF.

VLMFF harvesting and inseting

A line was drawn from the anterior superior iliac spine to the lateral border of the patella (Fig. 1a). The incision was made along the aforementioned line between the inferior and superior third. A suprafascial dissection was extended at least 5 cm medially and laterally ligating the skin perforators (Fig. 1b). The intermuscular septum between the vastus lateralis and rectus femoris was visualised and the curved line with lateral concavity, medial to the intermus-

Table I. Clinical data.

Case	Gender/age	pTNM	Surgery	Complications	Decannulation/ NG tube removal	Adjuvant therapy
1	F/70	yT2N0M0	Subtotal glossectomy + bilateral ND (I-IV)	None	5/13 days	No
2	M/59	T4N2cM0	Subtotal glossectomy + bilateral ND (I-V;I-IV)	None	8/16 days	Chemoradiation
3	F/69	pT2N0M0	Hemiglossectomy + ipsilateral ND (I-III)	None	4/9 days	No

ND: neck dissection

cular septum, was marked with a surgical pen and incised (Fig. 1c). Fascia was elevated medial-to-lateral to identify the intermuscular septum between the vastus lateralis and rectus femoris (Fig. 1d). The intermuscular septum was then gently dissected and the descending branch of the lateral circumflex femoral artery (DLCF) was identified along with the vastus lateralis motor nerve (Fig. 2a). A fascia paddle was then included over the vastus lateralis exceeding 20% of the desired muscle flap size in all directions (Fig. 2b). VLMFF was raised in a caudal-cephalic

direction using a harmonic ultrasonic scalpel (Harmonic Focus, Ethicon Endo-Surgery, Cincinnati, USA) according to the desired shape and respecting the neurovascular pedicle (Fig. 2c). Pedicle dissection continued until adequate neuro-vascular pedicle length was reached (Fig. 2d). Harvesting times were 40, 42 and 47 min, respectively. In cases 1 and 3, the DLCF artery was anastomised with the superior thyroid artery, while in case 2 with the facial artery. Venous anastomoses were performed in all cases end to side to the internal jugular vein. Nerve anastomo-

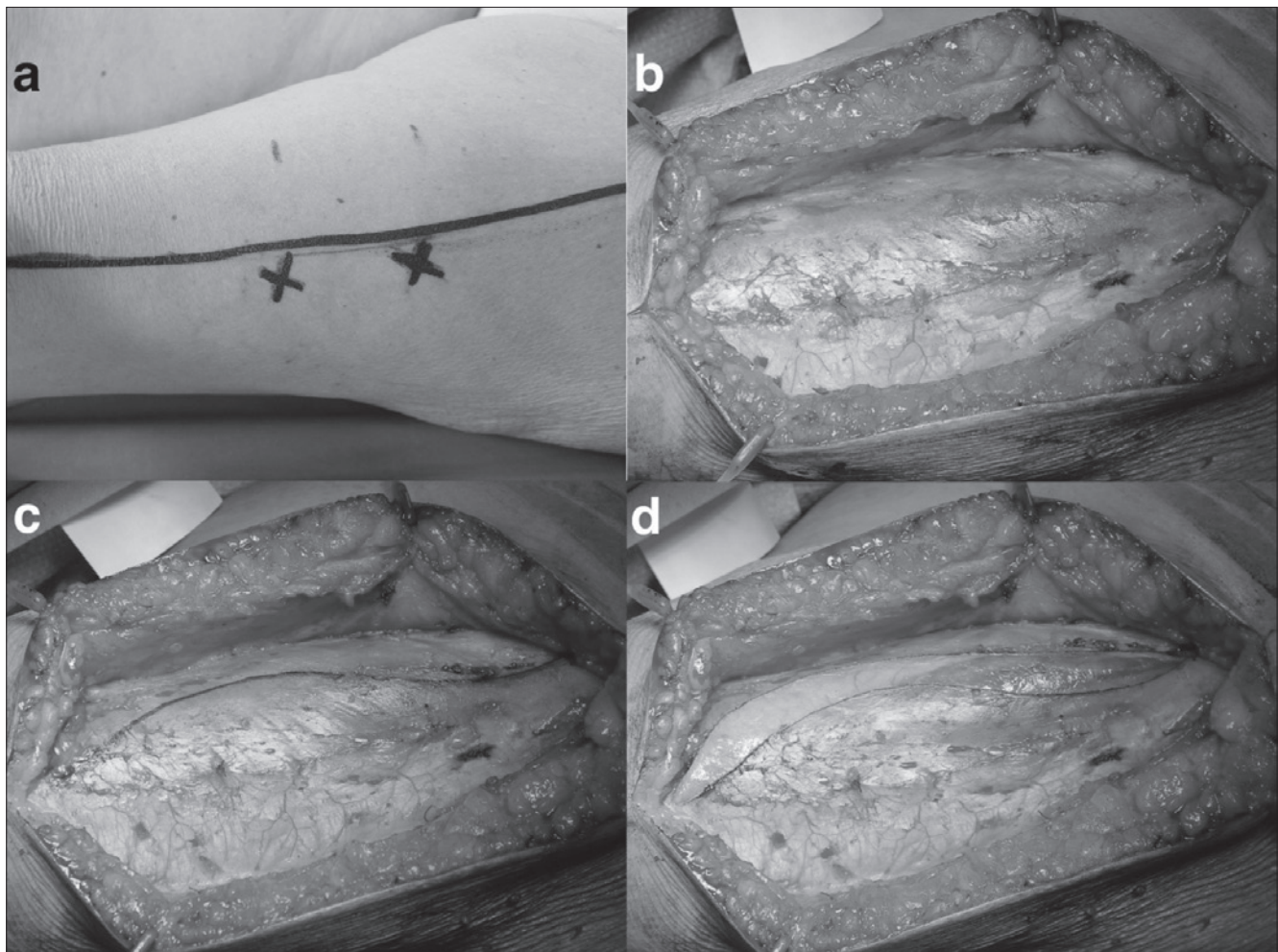


Fig. 1. VLMFF harvesting: a) incision line; b) suprafascial dissection; c) a curved line with lateral concavity is marked with a surgical pen; and d) elevated medial-to-lateral.

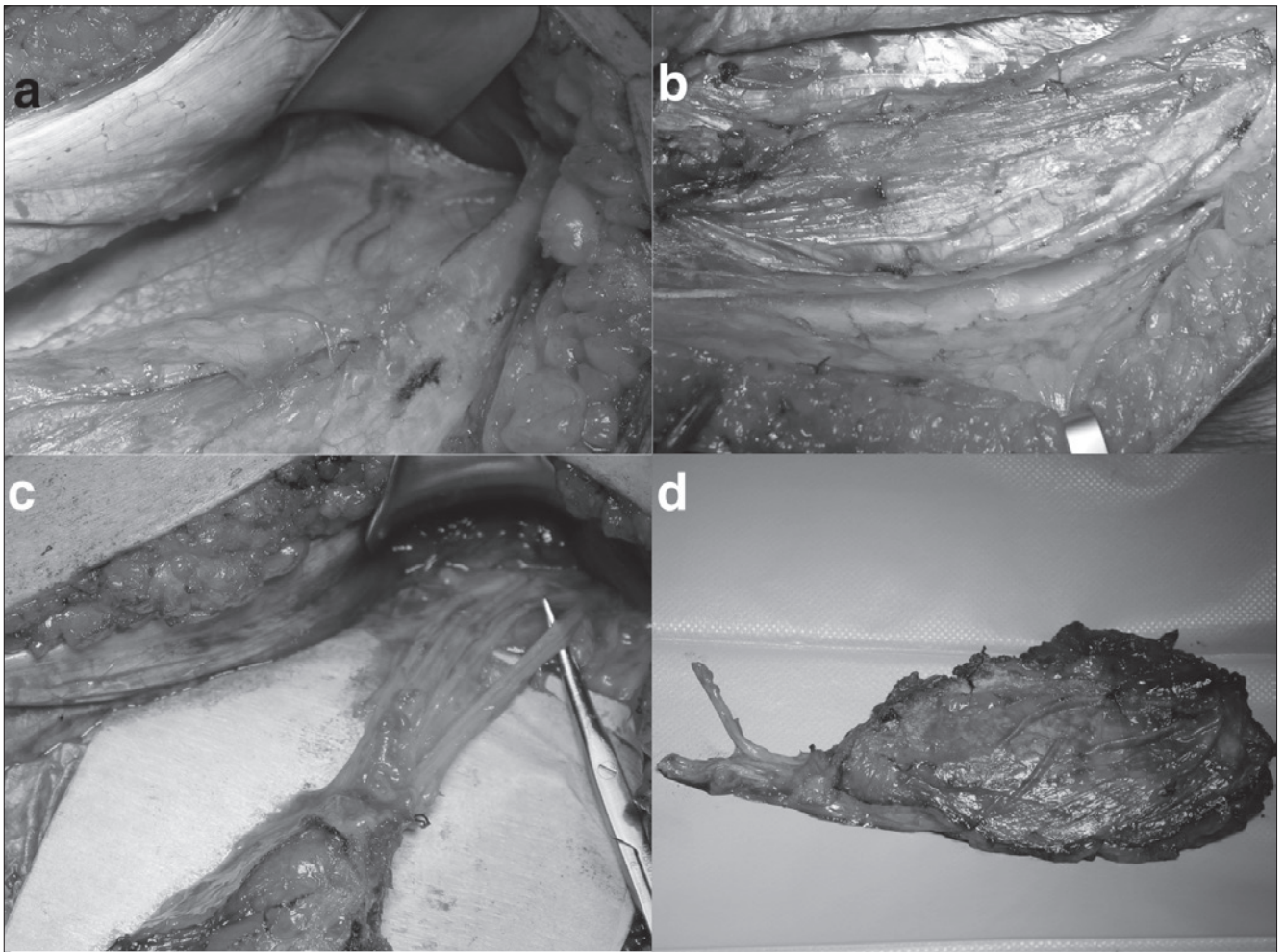


Fig. 2. VLMFF harvesting: a) the descending branch of the lateral circumflex femoral artery is identified; b) a fascia paddle is included over the vastus lateralis; c) VLMFF is raised including an adequate neuro-vascular pedicle; d) VLMFF completed harvesting.

ses between the hypoglossal nerve and vastus lateralis motor nerve was performed in all cases. In Figure 3 we show VLMFF inseting and 30-day post-operative results.

Discussion

The present study describes our preliminary experience of tongue reconstruction with VLMFF. VLMFF seems feasible, not technically demanding and safe. In our first three cases, we did not experience major complications such as necrosis, local infection or donor site impairment. VLMFF it is not time or budget consuming compared to the fascio-cutaneous and myocutaneous ALT variants since it does not imply further surgical steps and does not require adjunctive preoperative studies³. Harvesting of VLMFF required on average of 43 minutes.

VLMFF does not require harvesting of a skin island and consequently does not require preoperative study of vascular anatomy. This results in less closure tension and possibly in less donor site complications and better scar

healing. Due to its rich vascular supply, VLMFF does not require any perforator branch dissection either supra/sub fascial or intramuscular. This represents an important advantage since the aforementioned surgical steps imply a higher incidence of flap vascular supply impairment.

VLMFF has also some recipient site advantages. Thanks to the high number of muscular perforators, when the main vascular pedicle is preserved VLMFF could theoretically be shaped freely basing on the reconstruction necessity. However, we should point out that a 20-30% flap mass reduction due to muscular shrinkage should be expected. Another advantage is represented by the satisfactory cosmetic results. ALT flap classically includes a skin island that is responsible for a certain degree of color mismatch. In VLMFF, the use of muscle implies a better cosmetic result in tongue reconstruction. Moreover, thigh fascia protection adequately prevented fistula development in our 3 patients. A criticism to our technique could be in terms of donor site postoperative morbidity since the vastus lateralis muscle is sacrificed. However, as reported by Hanasono et al.⁴ in a series of 220 ALT free flap and later by Bi-

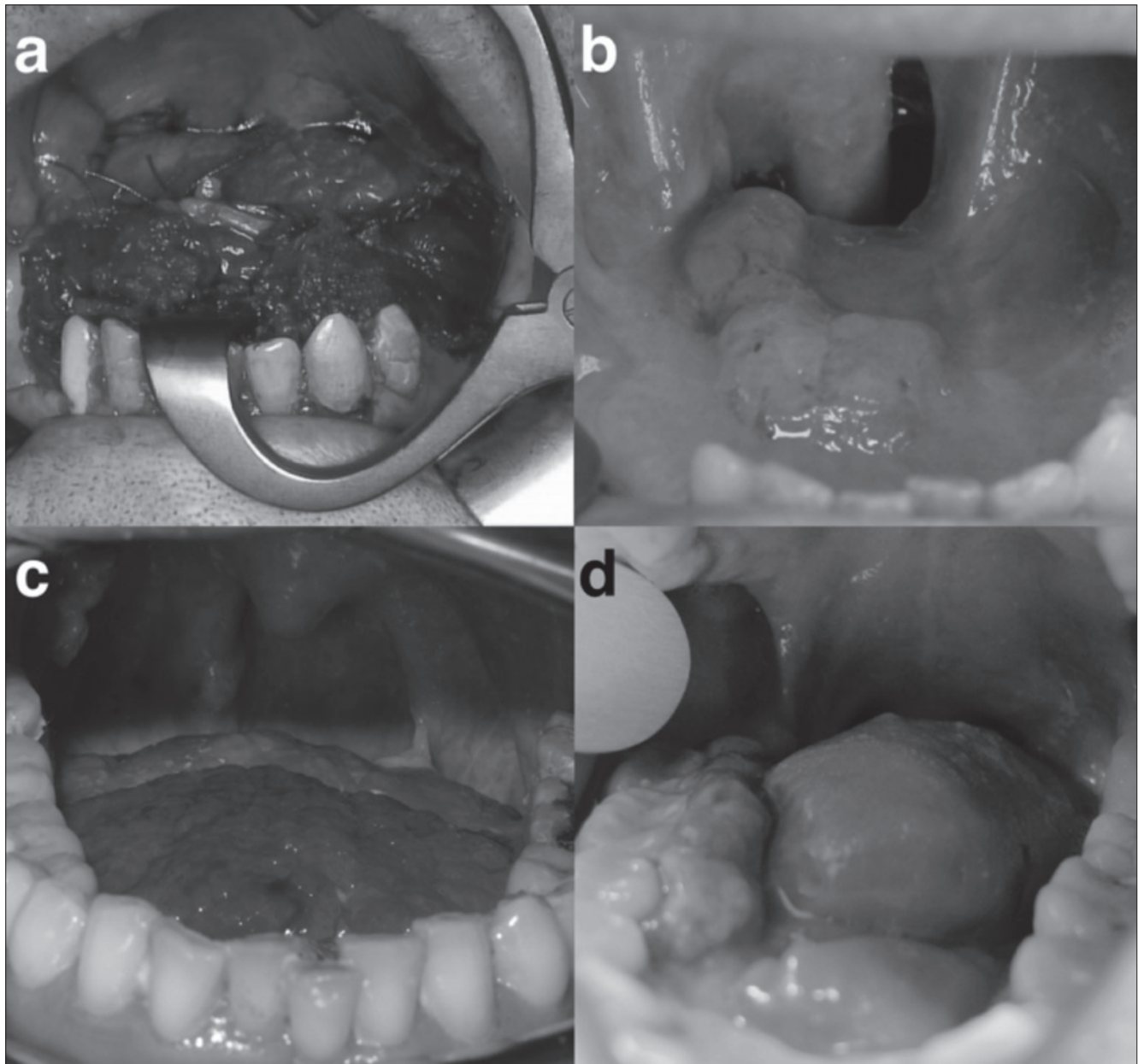


Fig. 3. Post-operative results: a) VLMFF inset in patient 2. Tongue reconstruction with VLMFF in patient 2 (b) and 1 (c), 30 days after surgery; d) tongue reconstruction with VLMFF in patient 3, 30 days after surgery.

anchi et al.⁵ in a series of 98 musculo-cutaneous ALT free flap, the harvesting of the muscular component does not seem to significantly increase donor-site morbidity. Hanasono et al.⁵ reported only an 8% of thigh weakness after muscle harvesting that was not associated with the amount of muscle harvested or motor nerve transection. Our 3 patients did not report thigh weakness and did not complain of any limitations in daily physical activity at 30 days after surgery.

Conclusions

The free VLMF flap could potentially offer unique advan-

tages in head and neck reconstruction, including adequate bulk when needed, optimal functional results and obliteration of dead space, thus preventing fistulas and infections with minimal morbidity.

Acknowledgements

Armando De Virgilio (corresponding author) has full access to all data in the study and takes responsibility for the integrity of the data and accuracy of data analysis.

References

- ¹ Cigna E, Rizzo MI, Greco A, et al. *Retromolar trigone recon-*

- structive surgery: prospective comparative analysis between free flaps. Ann Surg Oncol* 2015;22:272-8.
- ² Pellini R, Mercante G, Spriano G. *Step-by-step mandibular reconstruction with free fibula flap modelling. Acta Otorhinolaryngol Ital* 2012;32:405-9.
 - ³ Wolff KD, Grundmann A. *The free vastus lateralis flap: An anatomic study with case reports. Plast Reconstr Surg* 1992;89:469.
 - ⁴ Hanasono MM, Skoracki RJ, Yu P. *A prospective study of donor-site morbidity after anterolateral thigh fasciocutaneous and myocutaneous free flap harvest in 220 patients. Plast Reconstr Surg* 2010;125:209-14.
 - ⁵ Bianchi B, Ferri A, Ferrari S, et al. *The free anterolateral thigh musculocutaneous flap for head and neck reconstruction: one surgeon's experience in 92 cases. Microsurgery* 2012;32:87-95.

Received: January 10, 2016 - Accepted: March 4, 2016

Address for correspondence: Armando De Virgilio, Department of Otolaryngology-Head and Neck Surgery, Regina Elena National Cancer Institute, via Elio Chianesi 53, 00144 Rome, Italy. Tel. +39 06 52665065. Fax +39 06 52665066. E-mail: armando.devirgilio@gmail.com