

## CLINICAL TECHNIQUES AND TECHNOLOGY

# Auricular reconstruction of congenital microtia: personal experience in 225 cases

## *Ricostruzione auricolare in microtia congenita: esperienza personale in 225 casi*

M. ANGHINONI, C. BAILLEUL, A.S. MAGRI

Head and Neck Department, Maxillo-Facial Surgery Division, University Hospital of Parma, Italy

## SUMMARY

Microtia is a congenital disease with various degrees of severity, ranging from the presence of rudimentary and malformed vestigial structures to the total absence of the ear (anotia). The complex anatomy of the external ear and the necessity to provide good projection and symmetry make this reconstruction particularly difficult. The aim of this work is to report our surgical technique of microtic ear correction and to analyse the short and long term results. From 2000 to 2013, 210 patients affected by microtia were treated at the Maxillo-Facial Surgery Division, Head and Neck Department, University Hospital of Parma. The patient population consisted of 95 women and 115 men, aged from 7 to 49 years. A total of 225 reconstructions have been performed in two surgical stages basing of Firmin's technique with some modifications and refinements. The first stage consists in fabrication and grafting of a three-dimensional costal cartilage framework. The second stage is performed 5-6 months later: the reconstructed ear is raised up and an additional cartilaginous graft is used to increase its projection. A mastoid fascial flap together with a skin graft are then used to protect the cartilage graft. All reconstructions were performed without any major complication. The results have been considered satisfactory by all patients starting from the first surgical step. Low morbidity, the good results obtained and a high rate of patient satisfaction make our protocol an optimal choice for treatment of microtia. The surgeon's experience and postoperative patient care must be considered as essential aspects of treatment.

KEY WORDS: Ear • Ear reconstruction • Microtia • Auricular reconstruction

## RIASSUNTO

*La microtia è una malformazione congenita dell'orecchio caratterizzata da diversi gradi di severità sino alla totale assenza di ogni dettaglio riconoscibile (anotia). La complessità anatomica dell'orecchio esterno, nonché la necessità di assicurare una buona proiezione e simmetria con il padiglione auricolare controlaterale, ne rendono la ricostruzione particolarmente complessa. Lo scopo di questo lavoro è di presentare la nostra esperienza nella ricostruzione del padiglione auricolare e di analizzarne il risultato a medio e lungo termine. Dal 2000 al 2013 sono stati trattati 210 pazienti affetti da microtia monolaterale/bilaterale, per un totale di 225 ricostruzioni eseguite in due tempi chirurgici secondo la tecnica di Firmin, con l'apporto di alcune modifiche. Il primo tempo prevede il prelievo di cartilagine costale autologa che viene modellato e innestato. Nel secondo tempo, dopo 5/6 mesi, si realizza il solco retroauricolare con allestimento di lembo di fascia mastoidea e prelievo di cute libera. Il range di età varia da 7 a 49 anni; 115 pazienti sono di sesso maschile e 95 di sesso femminile. Verranno presentati i risultati, le complicanze a breve e a lungo termine, le indicazioni alla ricostruzione e le sue restrizioni. Sin dal primo tempo chirurgico la ricostruzione risulta esteticamente valida. Le limitate complicanze sia a breve che a lungo termine dimostrano la specializzazione del chirurgo e l'importanza di seguire attentamente il protocollo esposto.*

PAROLE CHIAVE: Orecchio • Ricostruzione Auricolare • Microtia

Acta Otorhinolaryngol Ital 2015;35:191-197

## Introduction

Microtia is a congenital anomaly of the external ear that can present with various degrees of severity from mild structural abnormalities to the complete absence of the external and middle ear. The malformation is characterised by unorganised cartilage remnants and a malpositioned lobule. The complete absence of any kind of external ear remnant is defined as anotia. Lobule displacement is related to the degree of facial hypoplasia, and the simultaneous absence of the auditory canal increases the severity of the anomaly.

The reported prevalence varies among countries from 0.83 to 17.4 per 10,000 births, and is considered to be higher in Hispanics, Asians, Native Americans and Andeans. Males are more often affected than females, the right ear is involved twice as frequently as the left and 70% of cases are unilateral<sup>1</sup>. Microtia can occur as an isolated defect or as part of a spectrum of anomalies, especially in a first or second arch syndrome (e.g. Franceschetti-Klein syndrome, hemifacial microsomia, Goldenhar syndrome). Auricular reconstruction is currently one of the most challenging plastic facial procedures because of the

complexity of the three-dimensional shape of the ear and its bilaterality, with the consequent need for symmetrical placement on both sides of the face. In addition, the result depends on the local conditions of the recipient site. Thus, if the region has never been treated, then evaluations of skin mobility in the mastoid region, various depressions in the same area for failure pneumatization of the mastoid cells, low position of the hairline and presence of ectopic remnants should be assessed. Different considerations exist if ear reconstruction has been attempted previously.

The results are often unreliable because many surgeons try to correct these deformities using a variety of techniques, but few have adequate experience. As a consequence, the success rate is frequently low<sup>2,3</sup>. The principles described by Tanzer<sup>4</sup> and Brent<sup>5,6</sup> are mainstays for all surgeons involved in ear reconstruction. They provide a scientific method, which serves as an excellent baseline for developing new ideas, underlining the necessity of a multistep procedure for auricular reconstruction to maximise the benefits of autologous rib grafting.

Various classifications are currently used to describe the microtic vestige of the ear. One of the most cited in the literature is that originally presented by Weerda in 1988<sup>7</sup> and modified by Aguilar<sup>8</sup>, which describes three degrees of severity. In the first degree, the auricle is anatomically present and normal in shape, but smaller than standard dimensions. In the second degree, the ear is malformed, but some identifiable structures are present. The third degree is classically defined as 'peanut', when the anatomical ear structures are almost completely or completely absent (anotia).

However, in our department, we prefer the classification used by Nagata<sup>9</sup>, who catalogued microtic ears as lobular type and conchal type deformities. The first type is sausage-shaped (comparable with the Aguilar third degree). The second type is characterised by underdevelopment of the lobule, concha, external acoustic meatus, tragus and intertragal incisure. It can be further divided into the small and large conchal subtypes. Moreover, Firmin described specific surgical incisions for each type of malformation<sup>10</sup>.

In our department we use a protocol based on an accurate clinical evaluation to obtain reliable results. First, we take into account whether the microtic ear is part of a malformative spectrum or an isolated sign in order to plan the most appropriate surgical procedure. In the former case, the timing must also be considered during planning of the skeletal reconstruction.

Afterwards, to obtain a symmetrical reconstruction, it is important to evaluate the dimensions and position of the uninvolved ear, using it as a model. Taking anthropometric measurements is an important step in the preoperative study of the patient. Various systems have been reported, by Posnik in 1993<sup>11</sup> until Firmin in 2001<sup>3,12</sup>, with different spatial relationships with the nasion and lip commissure

to determine the position of the reconstructed ear, an issue that requires special attention if the most symmetrical reconstruction possible is to be obtained.

Finally, we firmly believe that parental and patient compliance must also be considered. The success of this kind of surgery is related to both the aesthetic result and the cooperation and psychological postsurgical recovery of the patient<sup>13</sup>, based on realistic expectations.

In this article, we discuss the technical features that have allowed us to achieve stable and aesthetically satisfactory results. We will evaluate our approach, issues, implications and suggestions for further refinement of the surgical technique based on our experience.

### Clinical technique and technology

During the 13-year period from 2000 to 2013, a total of 210 patients diagnosed with congenital microtia (195 unilateral and 15 bilateral) underwent a total of 225 ear reconstructions in our department. 115 patients were male and 95 were female. The majority of patients were aged 8 to 12 years; the mean age was 15.05 years, with a range from 7 to 49 years. 12 patients had undergone a previous operation at another institution. 127 patients had an associated syndrome: 113 had otomandibular syndrome or Goldenhar syndrome, and 14 had Franceschetti-Klein syndrome.

An X-ray film template was fashioned before reconstruction using the contralateral ear as a model. The desired canting was marked in relation to the nasal dorsum. The distances from the helix to the external cantus and from the lobule to lip commissure are used to achieve a specular position. A two-step auricular reconstruction was planned. During the first stage the ipsilateral costal cartilages are harvested<sup>9</sup> to construct all anatomical segments. A slight oblique incision is made just above the costal margin, the muscle is divided and the sixth to eighth or ninth ribs are harvested. The cartilage used to construct the helix (8°) is removed with proper superficial and deep perichondrium, while the other ribs are removed leaving the deep perichondrium to permit regeneration and to avoid aesthetic defects in the chest profile. A suction drainage tube is positioned in the superficial layer to prevent haematoma formation, and a deep catheter is placed for infusion of anaesthetic drugs. The cartilage framework, obtained from a base block (sixth and seventh costal cartilages with synchondrosis, taking care to turn the anterior surface upside down to obtain a better profile), is carved to model the anti-helix, scapha and triangular fossa. The three-dimensional framework is then further refined using the film model to accentuate the fine details of the different structures (concha, helix and antihelix) located on different layers.

The various surgical steps have been reported in literature<sup>3,14</sup> and are not analysed in detail herein. The techniques vary according to the anatomical details of ear shape and projection. To obtain a good reproduction of a

single detail, its projection should be increased over the normal anatomical feature. We often need to overgraft the antihelix using fragments obtained from the cartilage work. More accurate carving of the inner side of the helix is advisable, taking care to reconstruct the helix in one piece to avoid fractures and future distortions. Finally, the tragus and anti-tragus, that surround the intertragal incisure, are modelled.

The cartilage segments are joined using fine stainless steel wire. The unused cartilage is banked in the subcutaneous tissue at the donor site for the second stage of the procedure. Firmin's skin incision<sup>10</sup> in the auricular region is either transfixated or a Z-type at the level of the remnant, respectively, if a typical conchal or lobule type microtia is present. The incision can be extended posteriorly in the mastoid region if it is necessary to transpose the lobule more posteriorly. The entire amorphous cartilage is excised and a cutaneous pocket is dissected with dimensions larger than those of the model for tension-free closure, avoiding the risk of skin necrosis and loss of the definition of cartilage convolutions. Good haemostasis is mandatory to avoid haematoma formation.

The framework is inserted and seated in its appropriate symmetrical position using the prefabricated template. Two vacuum suction drains are placed deep to the concha and around the helix respectively. After skin closure, the anatomical details of the framework are immediately evident with suction (Fig. 1). A non-compressive dressing is applied with paraffin gauze positioned to retain the reconstruction shape. The drains are maintained until the fourth to sixth postoperative day.

The second stage is generally carried out 6 months after the first. The procedure aims to increase the projection of the reconstructed ear and create the retroauricular sul-

cus. A skin incision is performed 3 to 5 mm posteriorly along the entire helix length. It is necessary to remove the hair bulbs present in the superior layer of the helix to improve the aesthetic result and the patient's psychological perception. The ear is elevated to obtain a correct auriculo-mastoid angle, and the cartilage banked in the first step is inserted in a semilunar shape beneath the framework<sup>15</sup> and fixed with nylon stitches. In our first seven cases, the cartilage graft was covered with a superficial temporal fascia and skin graft. After we started to use a mastoid fascia to cover the cartilage graft. Mastoid fascial flap harvesting is performed easily and rapidly. We begin with a curvilinear incision located posteriorly about 3 to 4 cm from the cartilage graft. The dissection is subfascial posteriorly and deepens subperiosteal anteriorly to obtain an anterior pedicle with sufficient random vascularisation.

To decrease the size of the area to be grafted, the skin of the mastoid region is dissected and advanced, removing the hair bulbs, as closely as possible toward the created retroauricular groove. Finally, a skin graft (split-thickness graft harvested from the adjacent scalp) is positioned on the posterior surface of the ear. The graft is sutured in place with multiple quilting sutures to prevent any tenting of the graft itself. The final dressing is made of packed paraffin gauze and a sponge and is kept in place for 1 week.

Complications that occurred after the first stage of the surgery included eight cases of central skin necrosis, all in the first period of our experience. They were treated under local anaesthesia by excision of the necrotic area and primary closure. It was necessary to use a strip of superficial temporal fascia in only two cases. Fifteen cases of partial skin necrosis of the upper helix were treated using a small strip of superficial temporal fascia.

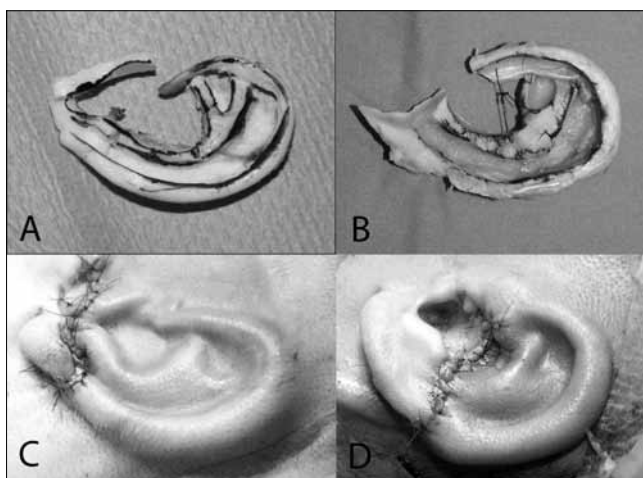
Patients experienced no severe complications, such as pneumothorax or pulmonary atelectasis. In two cases a small pleural lesion was immediately sutured with no postoperative consequences.

The exposure of metal wires, in agreement with the literature, was one of the complications that occurred during long-term follow-up.

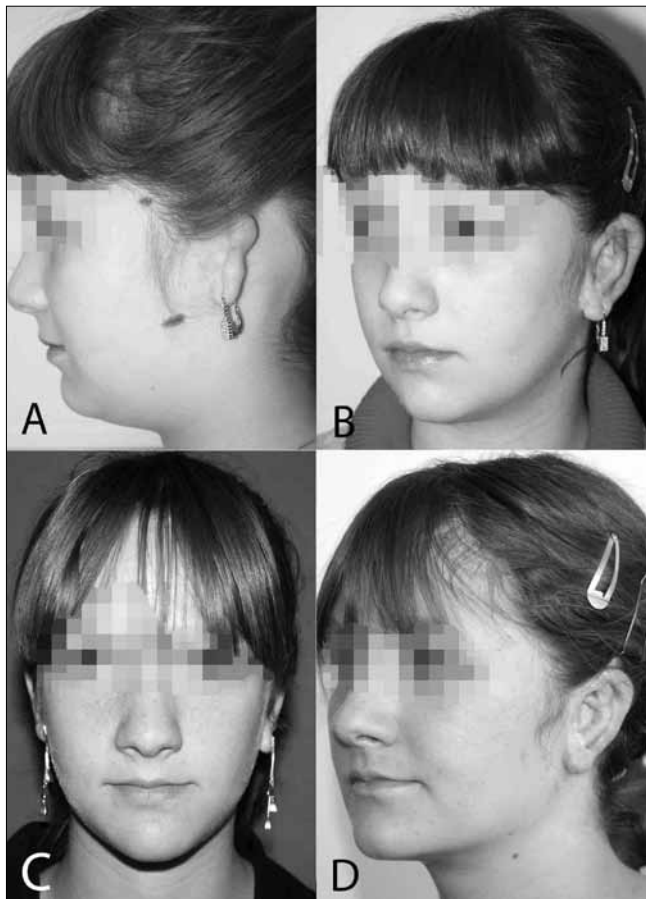
After the second stage, neither cartilage exposure nor fascial flap necrosis were seen. In 10 patients, small necrotic areas of the skin grafts were treated with antibiotic ointment and secondary healing.

All patients were followed up after the first stage every day until the 10<sup>th</sup> postoperative day. Each patient was then seen at intervals of 2 weeks, 1 month, 3 months and 5 months after the operation. After the second stage, patients were followed up every 3 days until the 15<sup>th</sup> postoperative day, then at intervals of 1 month, 3 months, 6 months, 1 year and yearly after the operation.

At 6 months after the second stage, the results are considered stable as no significant modification have been seen during the successive follow-up.



**Fig. 1.** A: complete framework reproducing all of the contours. B: framework in case of concha-type microtia reproducing all the contours except the tragus and antitragus. C: appearance at the end of the first stage procedure in a case of lobule-type microtia. D: aspect after the first stage procedure in a case of concha-type microtia.



**Fig. 2.** Case 1. A: preoperative appearance of a lobule-type microtia in a 9-year-old child. B: 1 year after surgery. C: after 3 years. D: after 10 years, we can appreciate the stability of the result.

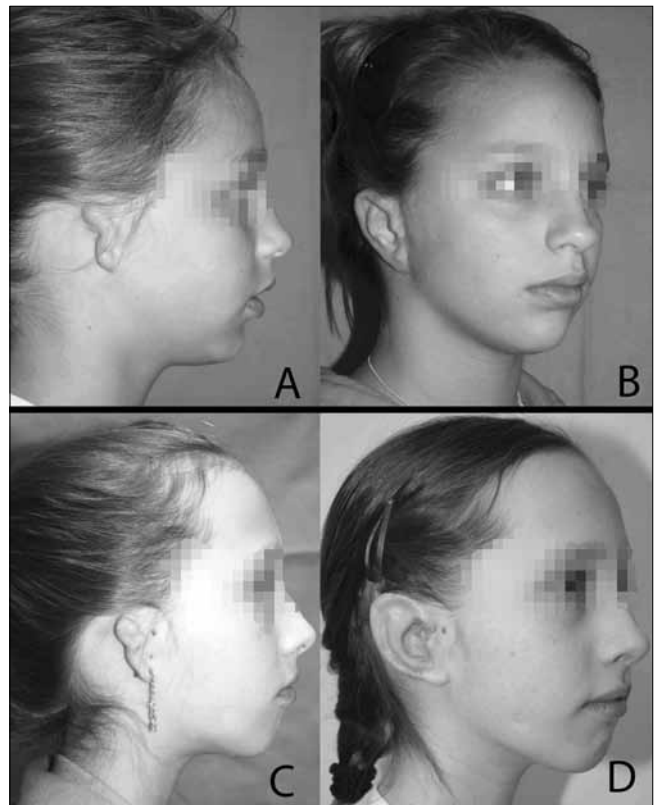
Figures 2-5 show the final results obtained in 6 patients who underwent the techniques described in this report.

### Discussion

The ear is characterised by a complex cartilage anatomy that is covered by a very thin skin; consequently, its surgical reconstruction is difficult.

To complicate this problem, this anatomical structure projects bilaterally and symmetrically from the sides of the face. In recent years, psychological distress associated with aesthetic deformity has been managed using several techniques, as reported by Brent<sup>5</sup>, Nagata<sup>14-17</sup> and Firmin<sup>10 18</sup>. These authors utilised different reconstructive protocols, although the foundation of all is the placement of a rigid autologous cartilage structure, adequately modelled, under the auricular skin.

Based on the experience of the above-mentioned authors<sup>6</sup>, the use of alloplastic materials (silicone, Medpor®, etc.) does not ensure stable results. These materials are often poorly tolerated, and can cause skin ulcers, infections and extrusions, and are often unable to withstand even small injuries that can occur at any time. Otherwise, the use of homologous cartilage showed a high degree of resorption and distortion



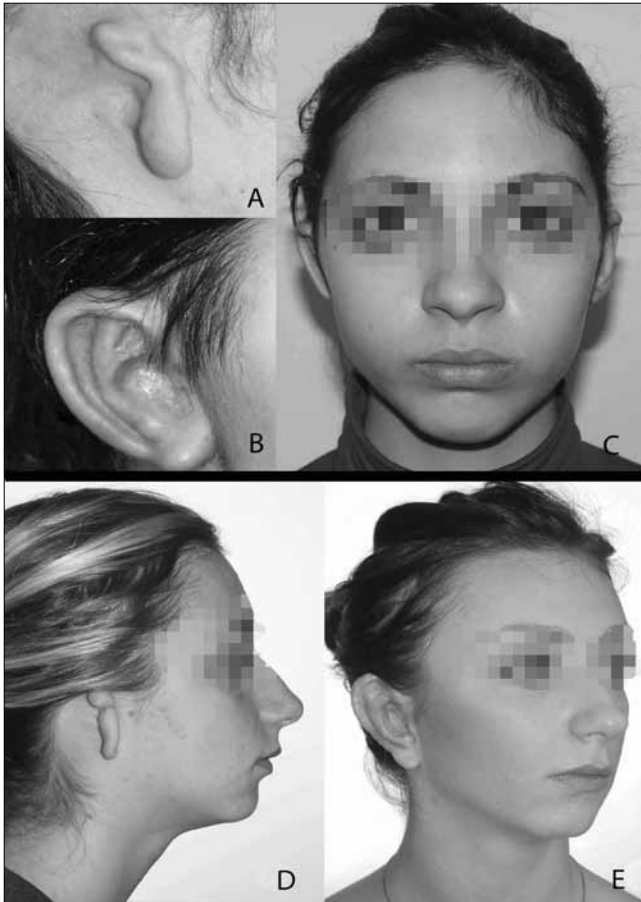**Fig. 3.** A: Case 2: preoperative appearance of a lobule-type microtia in an 11-year-old girl. B: postoperative appearance. C: Case 3: preoperative appearance of a lobule-type microtia in a 10-year-old patient. D: final appearance.

within a few months after surgery. Recently, some authors have described a method using porous polyethylene framework covered by a large temporoparietal fascia<sup>19</sup> to limit complications. According to Romo<sup>20</sup>, this technique does not require artistic or technical skills on the part of the surgeon, but, in our opinion, it gives poor individual results.

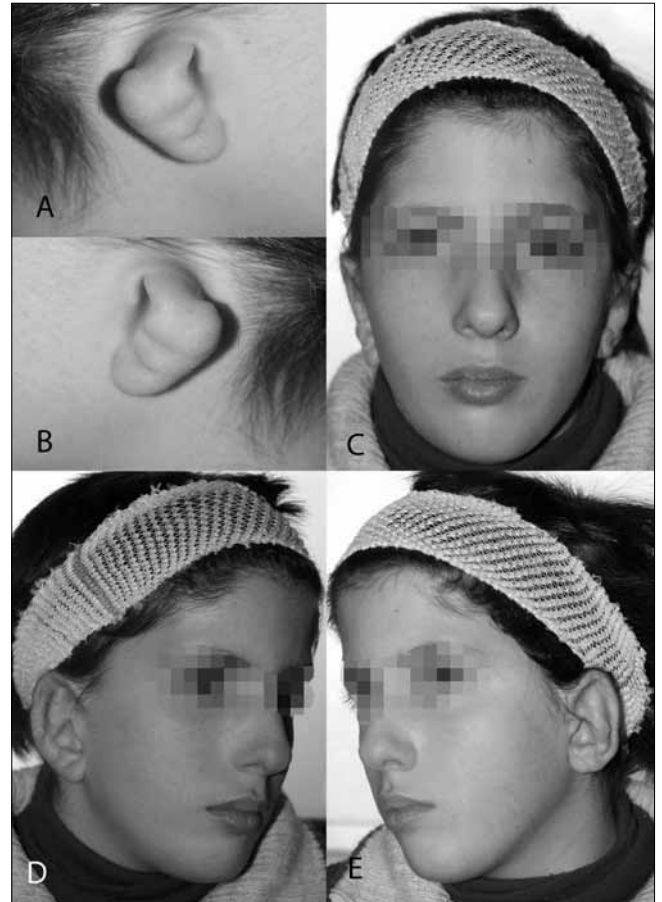
Therefore, the autologous cartilage graft is currently the gold standard for reconstruction: the aesthetic results are excellent, the surgical option is psychologically well accepted, there are no consequences in case of trauma, and normal physical activity is not limited.

A satisfactory result is the most difficult to obtain in patients with an associated syndrome<sup>21</sup>; in such cases, microtia correction must be included in the global treatment of the facial anomaly. The correct surgical timing to overcome typical difficulties may not be easy to determine<sup>12 22</sup>. Indeed, despite the fact that this reconstructive technique follows the same principles as standard microtia correction, the presence of facial asymmetries is a source of specific technical problems, such as properly positioning the ear in both the sagittal and vertical dimensions<sup>11 23</sup>. For this reason, many authors prefer to postpone microtia correction after the skeletal treatment of the facial asymmetry in order





**Fig. 4.** Case 4. A: preoperative appearance of a lobule-type microtia in a 10-year-old girl. B: reconstructed ear. C: final appearance. D: Case 5: preoperative appearance of a lobule-type microtia in a 15-year-old patient. E: appearance after 5 years.



**Fig. 5.** Case 6: bilateral concha-type microtia in a 8-year-old child. A: preoperative appearance of the right ear. B: preoperative appearance of the left ear. C: postoperative frontal view. D: right reconstructed ear. E: left reconstructed ear.

to have more symmetrical reference points (labial commissure, lateral canthus, eyebrow, mandibular angle, etc.) for correct positioning of the reconstructed ear<sup>22</sup>.

In our experience<sup>24</sup>, the ear reconstruction is the main request by paediatric patients and so can be performed before the skeletal correction. An exception is represented by cases of a severe mandibular hypoplasia in which there is a functional indication to reconstruct the mandible with a costal graft around 4 to 5 years of age.

In accordance with the literature<sup>10,25</sup>, we do not undertake reconstruction of the ear before the age of 9 to 10 years, for several reasons. Although the ear reaches approximately 85% of its final size at about 3 years of age, its growth continues until maturity of the individual (with small changes in size and position)<sup>26</sup>. The ear is considered fully developed by the age of 6 to 7 years, but it is better to wait for good development of the chest so that it is possible to obtain a sufficient amount of autologous costal cartilage. This permits the construction of a more elaborate structure without a risk of anatomical malformation of the donor site<sup>27,28</sup>. Finally, compliance of the patient is extremely important in the postoperative period, and cooperation is better in children aged at least 9-10 years.

In only one case we performed the surgical procedure in a patient with bilateral microtia at the age of 7 years because of emerging psychosocial problems.

In our experience, it is extremely important that parents help their children to understand the importance of the correct time for surgery, informing and reassuring them of a good future reconstruction outcome. While waiting for the reconstruction, we do not recommend the use of temporary prostheses<sup>29,30</sup> because they require a screw or removal of cartilaginous remnants for placement. The resulting scars may negatively interfere with the future reconstruction.

In patients with associated syndrome in whom there is an indication for surgical treatment of mandibular defects, if there are no specific functional problems, we postpone the mandibular surgery until 8 to 10 years of age. Thus, we take advantage of simultaneous performance of the ear reconstruction and mandibular procedures to reduce the number of operations needed for comprehensive rehabilitation of the face.

Different degrees of microtia and various concerns regarding the different anatomical features that require reconstruction exist. Normally, it is mandatory to reproduce the detailed anatomy of the entire ear. In certain cases the malformation does not include all the structures of the ear.

When the tragus, the intertragic incision, or the antitragus are normally developed, they will not be included in the framework. However, if these structures are present but deformed or insufficiently developed, it is better to sacrifice them and create a complete cartilage model.

In accordance with Firmin<sup>3</sup>, since 2002 the skin incision in the auricular region has been carried out with the transposition of a smaller lobe, but without the subcutaneous pedicle of the posterior skin flap as in Nagata's technique to avoid central necrosis. In this way, this complication is reduced, the surgical dissection is performed more easily and the position of the cartilaginous skeleton can be modulated. In our experience, a useful technique is to model a longer helix that reaches the lateral side of the lobe, avoiding an anatomical gap between the lobe and the helix that would be an aesthetically unpleasant feature.

At the end of the surgical procedure, we consider extremely important that two suction drains are placed and that the surgeon carefully assesses the immediate result which would be strictly similar with the final one. In case of doubt, immediate correction is mandatory. Possible minor future corrections must be avoided for greater patient comfort and to prevent additional manipulations and scarring. Moreover, the use of suction avoids haematoma formation, decreasing the risk of infection.

We believe that the thoracic incision should not exceed 5 to 7 cm in length. The decreased exposure of the operative field, partially compensated by the easy sliding of the dissected planes and by simple traction of the tissues, makes the harvesting slightly more difficult; however, it ensures the formation of a small scar.

Preservation of the deep perichondrium<sup>31</sup> reduces the risks of bleeding and perforation of the pleura and ensures greater solidity of the deep plane in the donor site. With correct suturing of the muscle planes, the morphological aspect of chest profile is almost normal.

We consider reduction of postoperative pain mandatory to maintain the young patient's confidence and cooperation. Initially, we used continuous intravenous infusion of morphine and painkillers; however, we now prefer intercostal infusion of a local anaesthetic, deep in the donor site, in three boluses per day for 3 days, taking care to close the drainage hood for 1 h after the infusion.

The stability of the projection obtained after the second surgical step is currently discussed in international literature. Problems associated with resorption and shifting of the cartilage graft, up to a total loss of the cephalo-auricular angle depth, have been reported<sup>32,33</sup>.

In general, unlike Nagata, we prefer to use a slightly larger (both in length and thickness) cartilage graft to counteract the inevitable shrinkage. We stabilise the graft with transfixing stitches from the cartilage to the conchal skin. In 20 cases, attempts to standardise the projection rate, we used a wedge-shaped Medpor deeply positioned, of

at least 6 mm in height. We insert one piece of cartilage, as a buffer, between the Medpor implant and the cartilage framework and a second piece posteriorly to protect the implant from the future injuries. The idea to overcome scar contraction with a non-absorbable material gave favourable results.

Recently, we also create a tunnel behind the framework to bury one or more pieces of cartilage under the retroauricular soft tissue after the elevation of the ear to obtain a correct projection<sup>10</sup>.

Another trick, applied in the second stage to maintain the depth of the retro-auricular sulcus, is the use of the superficial mastoid flap to cover only the new semilunar cartilage graft. Obviously, avoidance of dissection of the posterior face of the framework that is too superficial is mandatory to ensure skin graft survival. We have not experienced posterior exposure of the cartilage framework. Unlike the majority of authors<sup>3,15</sup>, we prefer an superficial mastoid fascial flap to a temporalis fascial flap, since the superficial mastoid flap is easier and faster to dissect and insert<sup>25</sup>. In the present study, we obtained excellent results, and no additional scarring, exposure of the cartilage grafts, or fascial necrosis occurred in any of the 210 patients treated.

We abandoned the use of the superficial temporal fascia after the first seven cases because of the advantage of its availability in cases of secondary complications. The skin graft for the sulcus is harvested from the adjacent region, which has the same texture as that of the healthy auricular region, with no residual scar and only minor pain<sup>18</sup>.

## Conclusions

Auricular reconstruction procedures, regardless of the degree of deformity (isolated microtia or severe facial asymmetry), require careful planning. The experience of the surgeon, surgical technique, favourable local conditions and compliance of the patient and family are the elements required to obtain satisfactory functional and aesthetic results.

In agreement with previous authors<sup>5,12</sup>, we believe that good outcome is dependent on the accuracy, patience and training of the surgeon in terms of modelling of ear cartilage details and maintaining the skin integrity of the auricular region.

In cases involving unfavourable local conditions (presence of scar tissue secondary to severe trauma, burns, or secondary reconstructions), additional techniques can be performed with different results, but the outcome will probably be less satisfactory.

## References

- 1 Luguetti DV. *Microtia: epidemiology and genetics*. Am J Med Genet A 2012;158A:124-39.
- 2 Brent B. *Microtia repair with rib cartilage grafts. A review of personal experience with 1000 cases*. Clin Plast Surg 2002;29:257-71.

- <sup>3</sup> Firmin F. *State of the art autogenous ear reconstruction in cases of microtia*. *Adv Otorhinolaryngol* 2010;68:25-52.
- <sup>4</sup> Tanzer RC. *Total reconstruction of the external ear*. *Plast Reconstr Surg* 1959;23:1-15.
- <sup>5</sup> Brent B. *Auricular repair with autogenous rib cartilage grafts: two decades of experience with 600 cases*. *Plast Reconstr Surg* 1992;90(Suppl 3):355-74.
- <sup>6</sup> Brent B. *Technical advances in ear reconstruction with autogenous rib cartilage grafts: personal experience with 1200 cases*. *Plast Reconstr Surg* 1999;104:319-34.
- <sup>7</sup> Weerda H. *Classification of congenital deformities of the auricle*. *Facial Plast Surg* 1988;5(Suppl 5):385-8.
- <sup>8</sup> Aguilar EF. *Auricular reconstruction of congenital microtia (grade III)*. *Laryngoscope* 1996;106(Suppl 82):1-26.
- <sup>9</sup> Nagata S, Fukuda O. *A new reconstruction for the lobule type microtia*. *Jpn J Plast Reconstr Surg* 1987;7:689.
- <sup>10</sup> Firmin F. *A novel algorithm for autologous ear reconstruction*. *Semin Plast Surg* 2011;25:257-64.
- <sup>11</sup> Posnick JC, Al-Qattan MM, Whitaker LA. *Assessment of the preferred vertical position of the ear*. *Plast Reconstr Surg* 1993;91(Suppl 7):1198-203.
- <sup>12</sup> Firmin F, Guichard S. *La Microtie dans la dysplasie oto-mandibulaire*. *Ann Chir Plast Esthet* 2001;46:467-77.
- <sup>13</sup> Quatela VC, Thompson SK, Goldman ND. *Microtia reconstruction*. *Facial Plast Surg Clin North Am* 2006;14(Suppl 2):117-27.
- <sup>14</sup> Nagata S. *Modification of the stages in total reconstruction of the auricle: part I. Grafting the three-dimensional costal cartilage framework for lobule-type microtia*. *Plast Reconstr Surg* 1994;93:221-30.
- <sup>15</sup> Nagata S. *Modification of the stages in total reconstruction of the auricle: part IV. Ear elevation for the constructed auricle*. *Plast Reconstr Surg* 1994 ;93:254-66.
- <sup>16</sup> Nagata S. *Modification of the stages in total reconstruction of the auricle: part II. Grafting the three-dimensional costal cartilage framework for concha-type microtia*. *Plast Reconstr Surg* 1994;93:231-42.
- <sup>17</sup> Nagata S. *Modification of the stages in total reconstruction of the auricle: part III. Grafting the three-dimensional costal cartilage framework for small concha-type microtia*. *Plast Reconstr Surg* 1994;93:243-53.
- <sup>18</sup> Firmin F. *Ear reconstruction in cases of typical microtia. Personal experience based on 352 microtic ear corrections*. *Scand J Plast Reconstr Hand Surg* 1998;32(Suppl 1):35-47.
- <sup>19</sup> Reinisch JF, Lewin S. *Ear reconstruction using a porous polyethylene framework and temporoparietal fascia flap*. *Facial Plast Surg* 2009;25(Suppl 3):181-9.
- <sup>20</sup> Romo T 3<sup>rd</sup>, Reitzen SD. *Aesthetic microtia reconstruction with Medpor*. *Facial Plast Surg* 2008;24:120-8.
- <sup>21</sup> Figueroa A, Pruzansky S. *The external ear, mandible and other components of hemifacial microsomia*. *J Max Fac Surg* 1982;10:200-11.
- <sup>22</sup> Yamada A. *External ear reconstruction in hemifacial microsomia*. *J Craniofac Surg* 2009;20(Suppl 2):1787-93.
- <sup>23</sup> Thomson HG, Correa A. *Unilateral microtia reconstruction: is the position symmetrical?* *Plast Reconstr Surg* 1993;92(Suppl 5):852-7.
- <sup>24</sup> Anghinoni M. *Malattie rare, malattie genetiche e distretto oro-cranio-facciale. Parte seconda; Sindrome del I e II arco branchiale*. Pisa: Edizioni ETS; 2002. p. 203.
- <sup>25</sup> Siegert R, Weerda H, Magritz R. *Basic techniques in autogenous microtia repair*. *Facial Plast Surg* 2009;25:149-57.
- <sup>26</sup> Bauer BS, Lin JL. *Ear, Microtia* [<http://emedicine.medsxope.com/article/129008>].
- <sup>27</sup> Kanetoshi O, Kiyoshi N, Eiichi O. *Chest wall deformities and thoracic scoliosis after costal cartilage graft harvesting*. *Plast Reconstr Surg* 1997;99:1030-6.
- <sup>28</sup> Thomson HG, Kim TY, Ein H. *Residual problems in chest donor sites after microtia reconstruction: a long-term study*. *Plast Reconstr Surg* 1993;95:961-8.
- <sup>29</sup> Wilkes GH, Wolfaardt JF, Dent M. *Osseointegrated alloplastic versus autogenous ear reconstruction: criteria for treatment*. *Plast Reconstr Surg* 1994;93(Suppl 5):967-79.
- <sup>30</sup> Thorne CH, Brect LE, Bradley JP. *Auricular reconstruction: indications for autogenous and prosthetic techniques*. *Plast Reconstr Surg* 2001;15:1241-52.
- <sup>31</sup> Nagata S. *A new method of total reconstruction of the auricle for microtia*. *Plast Reconstr Surg* 1993;92:187-201.
- <sup>32</sup> Tai Y, Tanaka S, Fukushima J. *Refinements in the elevation of reconstructed auricles in microtia*. *Plast Reconstr Surg* 2006;117:2414-23.
- <sup>33</sup> Hou X, Zhang Q, Liu T. *Modification of the technique of ear framework fabrication for congenital microtia*. *J Craniofac Surg* 2012;23:1296-300.

Received: July 31, 2014 - Accepted: November 8, 2014

Address for correspondence: Marilena Anghinoni, Head and Neck Department, Maxillo-Facial Surgery Division, University Hospital of Parma, via Gramsci 14, 43100 Parma, Italy. Tel. +39 0521 703109. Fax: +39 0521 703080. E-mail: manghinoni@ao.pr.it