

# Giant osteoid osteoma of ethmoid sinus: role of functional endoscopic sinus surgery

## *Osteoma osteoide gigante dell'etmoide: ruolo della chirurgia funzionale endoscopica sinusale*

F. BERTOLETTI, B. CAPOLUNGHY, G. BERTOLINI, F. CASCIO<sup>1</sup>, A.M. BRACCI<sup>2</sup>

Department of Otorhinolaryngology, "Mellino Mellini" Hospital, Chiari-Iseo (BS); <sup>1</sup>Department of Otorhinolaryngology, "Piemonte" Hospital, Messina; <sup>2</sup>Department of Otorhinolaryngology, "Città di Brescia" Hospital, Brescia, Italy

### Key words

Paranasal sinuses • Benign lesion • Osteoma • Surgical treatment • Endoscopic surgery

### Parole chiave

Seni paranasali • Lesioni benigne • Osteoma • Trattamento chirurgico • Chirurgia endoscopica

### Summary

A case of giant ethmoid osteoma treated by functional endoscopic sinus surgery is described. The tumour was closely adherent to the surrounding anatomical structures – lamina papyracea, cribriform plate, sphenoid-ethmoidal recess – and protruded into the nasopharynx. Complete removal of the tumour, under general anaesthesia, using intranasal drill and diode L.A.S.E.R. was achieved. The principal aspects in favour of this surgical technique *vs.* open procedures (fronto-basal craniotomy, supraciliary and coronal approach) are discussed. Functional endoscopic sinus surgery is herewith concluded to be a convenient and safe technique with advantages over the open procedures, widely used in the past. The reduced morbidity, length of hospital stay and better cosmetic results are distinct advantages of this technique that has the potential to become the treatment of choice for selected ethmoid tumours, such as giant osteoma, described in the present report.

### Riassunto

*Gli Autori presentano il caso di un osteoma gigante del seno etmoidale trattato con chirurgia funzionale endoscopica sinusale. La neoplasia estesa al rinofaringe e con stretti rapporti con le strutture anatomiche circostanti – lamina papiracea, lamina cribra, recesso sfeno-etmoidale – è stata completamente asportata attraverso le vie naturali, in anestesia generale, con impiego di fresa e L.A.S.E.R. diodi. Dopo un'accurata esposizione della tecnica chirurgica utilizzata, gli Autori discutono gli aspetti principali a favore della metodica confrontandone i vantaggi rispetto alle tecniche aperte: craniotomia fronto-basale, incisione coronale, approccio sopraciliare. Essi concludono che la chirurgia funzionale endoscopica sinusale offre un'alternativa conveniente e sicura rispetto alle procedure aperte, trovando indicazioni sempre più frequenti in casi selezionati. La tecnica endoscopica permette: una visione diretta della lesione, una asportazione con salvaguardia delle strutture anatomiche circostanti, minimi rischi di emorragia, una degenza ospedaliera ridotta e non si pongono problemi di ordine estetico. La metodica può divenire il trattamento di scelta per casi selezionati di tumori dell'etmoide, come il caso descritto in questa nota.*

## Introduction

Osteomas are benign tumours, rarely found in the paranasal sinuses<sup>1</sup>, even though they represent the most frequent bone neoplasias arising from the facial bones<sup>2</sup>, as well as fibrous dysplasia and ossifying fibroma<sup>3,4</sup>. The two latter lesions may have a similar radiological appearance but their borders are usually less well defined than those of osteomas<sup>5</sup>. Osteomas may occur in the long bones and, in this case, they are invariably juxtacortical<sup>6</sup>.

The benign bone lesions – osteoma, osteoid osteoma and osteoblastoma – are characterized as bone-forming since the tumour cells produce osteoid or mature

bone. Although osteoid osteoma and osteoblastoma appear histologically very similar, their clinical presentations and distribution in the skeleton are, however, distinct: osteoid osteoma is usually accompanied by nocturnal pain, promptly relieved by salicylates; osteoblastoma arises predominantly in the axial skeleton, spinal lesions constituting one-third of reported cases<sup>6</sup>.

Osteomas of paranasal sinuses occur mainly in the frontal and ethmoid sinus, maxillary or sphenoid sinus are very rarely seen<sup>7-9</sup>. Frontal sinus osteomas account for 57% of all paranasal sinus osteomas<sup>10</sup>, with an incidence of 0.1 to 3%<sup>11</sup>. Osteoma of the mandible, temporal bone and mastoid have been de-

scribed. Age at presentation is most commonly the second to fifth decade, with a male:female ratio of approximately 3:1<sup>12</sup>.

Paranasal sinus osteomas have a tendency to grow slowly. Koivunen et al.<sup>13</sup> report 1.61 mm/yr (range 0.44 to 6.0 mm/yr) as the mean growth rate. For this reason, they are generally asymptomatic and discovered only as a coincidental radiological finding. Exceptionally, they may be locally destructive and aggressive with possible intra-cranial complications<sup>10</sup>. The origin of these tumours has been considered as due to maldevelopment of embryologic tissue, trauma or infections<sup>14</sup>. According to the first theory, some embryologic tissue in the ethmoid sinus can be activated by inflammation or a physiological growth phenomenon, achieving osteoplastic capability. Some Authors have suggested an ethnic variation<sup>15</sup>. Symptoms of ethmoid osteoma occur earlier than osteoma of the frontal sinus on account of the small volume of the sinusal cavity<sup>16</sup>. Headache localized over the area of osteoma, facial pain or deformity, rhinorrhea, anosmia, epistaxis are common symptoms; sometimes patients refer to sinusitis or ocular troubles. Gardner syndrome is described as an association of paranasal osteomas, intestinal polyps, dermoid cysts and fibromas.

Histopathologically, osteoma is hard and lobulated with an ivory-like appearance, often mixed with a coarse granular component. The bone is compact or cancellous, with vascular or connective tissue components. Some Authors have suggested that the bone localization of osteoma influences the histopathological architecture: in osteomas of suture origin, the fibrovascular component is significantly reduced<sup>17</sup>.

A case of giant osteoid osteoma of ethmoid sinus, treated by functional endoscopic sinus surgery (FESS), using a 30 degrees, 2.5 mm endoscope, intra-nasal drill and diode L.A.S.E.R. is described. Complete osteoma removal via endonasal surgery was achieved.

The progress made in endoscopic sinus surgical techniques makes it an excellent method for use in the diagnosis and treatment of paranasal diseases avoiding the major complications and cosmetic problems caused by traditional external procedures (osteoplastic frontal sinus approach with coronal incision, maxilloethmoidectomy, supraciliary approach).

## Case report

A 52-year-old-male was referred to us complaining of facial pain, headache, visual disturbance, transitory epistaxis. He had a history of chronic sinusitis. The ear, nose and throat examination revealed the presence of a large mass on the left nasal fossae. Pre-operative radiographic diagnostic work-up in-

cluded axial high resolution computed tomography (HRCT-scan) of the paranasal sinuses with secondary coronal reconstructions to determine side, volume and origin of the osteoma. HRCT-scan showed: "... expansive osseous lesion occupying the entire ethmoid sinus ... extending upwards to the roof of the sinus and the cribriform plate ... laterally to the lamina papyracea without exceeding the limits of the orbit, ... the rear side of the mass protrudes beyond the choanal plane in the nasopharynx, widening the sphenoid-ethmoidal recess and partially occupying the left sphenoid sinus. The paranasal lesion obliterates the middle meatus and the hiatus semilunaris, it includes the unciniate process and the medium turbinate. Frontonasal recess is occluded by the mass ..." (Fig. 1).

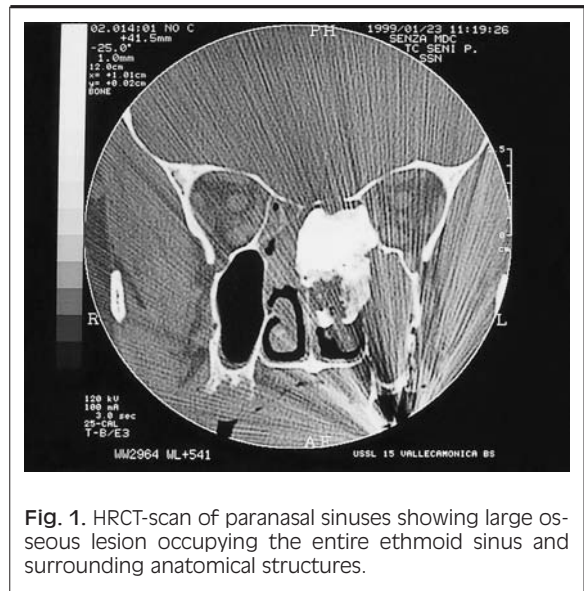


Fig. 1. HRCT-scan of paranasal sinuses showing large osseous lesion occupying the entire ethmoid sinus and surrounding anatomical structures.

## Surgical technique

The operation was performed under general anaesthesia by endotracheal intubation. Functional endoscopic sinus surgery, using a 2.5 mm, 30 degrees endoscope, intranasal drill and diode L.A.S.E.R. (Medilas®, Dornier), was performed. Shrinking of the nasal mucosa was achieved with 1:1000 epinephrine-rinsed cotton plugs, removed 10 minutes after application.

The middle turbinate was partially excised, an incision in the unciniate process was made, the ethmoid bulla was resected, the maxillary sinus ostium was identified to determine the plane of the lamina papyracea.

On account of the huge dimensions of the tumour and

its adhesion to the surrounding anatomical structures, complete removal of the osteoma was achieved in two different surgical stages:

- 1) first, several cavities (1.5 mm in diameter) were created in the anterior side of the osseous mass, using an intranasal drill; diode L.A.S.E.R. fibres (Type D-6100-BF, K 1008084,  $\varnothing$  1.0 mm) were positioned in each cavity and a dismission of energy (4 watt x 4 min) was consecutively performed in each one. Each diode L.A.S.E.R. fibre resulted in coagulation of the inorganic component of the tumour without involving the osteoblastic cells, so that the repeated use of the interstitial L.A.S.E.R. fibres made a partial coarctation and reduction of the volume of the ethmoid osteoma and its separation from the sinus wall;
- 2) in the second stage, the reduced osteoma was drilled out infero-laterally to supero-medially using an intranasal drill and completely removed. Care was taken around the supero-lateral boundaries of the osteoma adjacent to the skull base and orbit. Residual osteoma was then, finally, completely separated from the lamina papyracea using a double-ended blunt elevator. The excised tumour weighed 30 g and was >4 cm in diameter (Fig. 2).

After the procedure, haemostasis was achieved using 1:1000 epinephrine-rinsed cotton plugs which were later removed. Gauzes were lightly packed to prevent post-operative haemorrhage and were removed 48 hours later.

There were no severe complications such as haemorrhage, ocular disturbance, loss of vision. Cerebrospinal fluid fistula occurred in the early post-operative period, but no surgical treatment was required. The orbital ecchymosis was insignificant.

The histopathological examination confirmed: "*Osteoid osteoma of the paranasal sinuses*".

The patient was observed at follow-up with nasendoscopy which confirmed normal re-epithelialization within 4 weeks of surgery. The HRCT-sinus-scan performed 4 months and again 3 years post-operatively confirmed no residual osseous tumours (Fig. 3).

## Discussion

Management of paranasal osteomas remains controversial. Some Authors advise resection when these lesions are symptomatic or when they exhibit rapid growth. Savic and Djeric<sup>18</sup> suggested surgical removal for osteomas extending beyond the boundaries of the frontal sinus, those which continue to enlarge, those localized in the region adjacent to the frontonasal recess, those associated with chronic sinusitis and osteomas of the ethmoid sinus, irrespective of size.

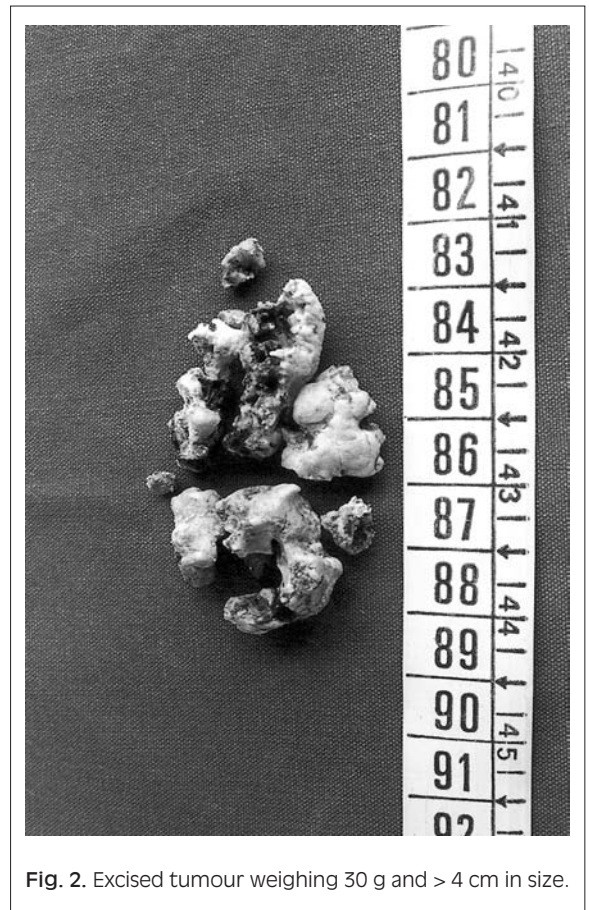


Fig. 2. Excised tumour weighing 30 g and > 4 cm in size.

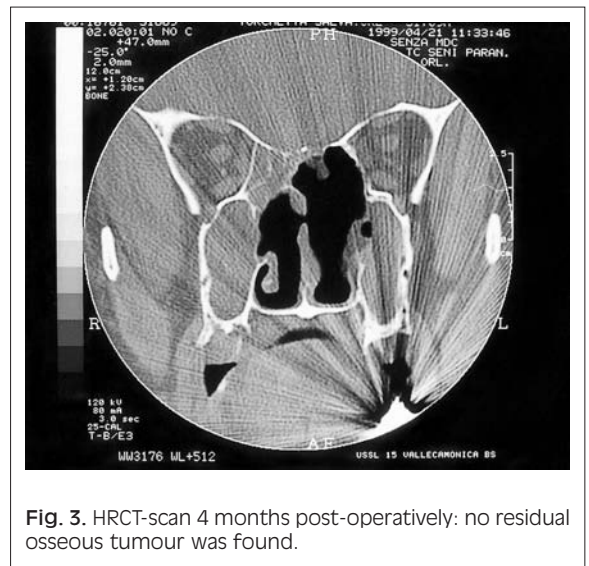


Fig. 3. HRCT-scan 4 months post-operatively: no residual osseous tumour was found.

Traditionally, resection has been performed by means of a variety of open approaches: osteoplastic flap

technique with coronal incision, maxilloethmoidectomy, supraciliary approach or direct anterior surgical exposure. Although open surgical excision may be necessary in some specific conditions, there are still several points worth mentioning on account of the risk of severe complications, such as: cerebrospinal fluid fistulas, haemorrhage, damage to the surrounding structures, increased blood loss and aesthetic problems.

Recently, FESS has offered an alternative approach and has been considered to be a valuable contribution in the management of paranasal sinus osteoma. Since starting with the treatment of inflammatory paranasal disorders, the endonasal approach has been extended to many other applications, such as surgery in orbital diseases, choanal atresia or closure of cerebrospinal fluid fistulas, tumours of the nose and anterior skull base<sup>12</sup>.

Functional endoscopic sinus surgery, as in the present case, offers the advantage of closer and more direct visualization of the anatomy during the operation, as well as avoiding damage to neighbouring structures, haemorrhage was more easily stopped and no cosmetic complications occurred.

A pre-requisite for complete endonasal tumour resection is adequate access to all tumour borders. If the osteoma is exceptionally large and broadly attached to the ethmoidal borders, as in the case described here, the tumour can be reduced in size with the drill, before complete removal<sup>19</sup>. In our personal experience, the osteoma has been completely excised using the intranasal drill and interstitial L.A.S.E.R. fibre which have allowed its separation from the borders of the ethmoid sinus, nasal cavity and lamina papyracea.

Some Authors have described the removal of giant paranasal osteoma, with traditional procedures,

weighing 110 g<sup>20</sup> and with a diameter > 3 cm<sup>11</sup>. Most Authors, however, describe the common size osteoma: Schick et al.<sup>12</sup>, in a retrospective evaluation of 34 patients with frontoethmoidal osteomas, reported a diameter ranging from 8 to 35 mm (mean: 17 mm). When the osteoma involves severe extension to the frontal sinus, FESS must be associated with the external standard procedure<sup>21</sup>. The most appropriate choice of the surgical approach, in frontoethmoidal osteomas, depends, in general, upon the location, volume and side of the osteoma, on the anatomical conditions, such as the anterior-posterior diameter of the frontal recess, and on possible extrasinusal extension<sup>12</sup>.

The endonasal approach should be considered also for frontal sinus osteoma if: 1) sufficient frontal sinus access can be achieved endonasally; 2) the osteoma is located medially to a virtual sagittal plane through the lamina papyracea, and 3) the tumour base is at the lower part of the posterior frontal sinus wall<sup>12</sup>.

## Conclusions

The 30 degrees nasoendoscope approach, using an intranasal drill, provides a good operative field and is a safe and effective technique. It has certain advantages over the open procedures widely used in the past, such as reduced morbidity, length of hospital stay and better cosmetic results.

Personal experience using the diode L.A.S.E.R. with interstitial fibre and intranasal drill has allowed complete eradication of the osteoma and it may be concluded that functional endoscopic sinus surgery has the potential to become the treatment of choice for selected ethmoid tumours, such as, for example, giant osteoma described in the present report.

## References

- Sudhoff H, Theegarten D, Luckaupt H. *Osteoma of the maxillary sinus*. Laryngorhinootologie 2001;80:275-7.
- Bourgeois P, Fichten A, Louis E, Vincent C, Pertuzon B, Assaker R. *Frontal sinus osteomas: neuro-ophthalmological complications*. Neurochirurgie 2002;8:104-8.
- Brodish BN, Morgan CE, Sillers MJ. *Endoscopic resection of fibro-osseous lesions of the paranasal sinuses*. Am J Rhinol 1999;13:11-6.
- Tsai TL, Ho CY, Guo YC, Chen W, Lin CZ. *Fibrous dysplasia of the ethmoid sinus*. J Chin Med Assoc 2003;66:131-3.
- Margo CE, Wess A, Habal MB. *Psammomatoid ossifying fibroma*. Arch Ophthalmol 1986;104:1347-51.
- Greenspan A. *Benign bone-forming lesions: osteoma, osteoid osteoma, and osteoblastoma. Clinical, imaging, pathologic, and differential considerations*. Skeletal Radiol 1993;22:485-500.
- Frenguelli A. *Osteoma del seno mascellare*. Perugia: Ann. Facoltà di Medicina e Chirurgia 1976;34:499-506.
- Simoncelli C, Gallucci L, Ricci G, Capolunghi B. *Osteoma del seno mascellare di inconsuete dimensioni*. Otorinolaringologia 1989;39:487-90.
- Tsai CJ, Ho CY, Lin CZ. *A huge osteoma of paranasal sinuses with intraorbital extension presenting as diplopia*. J Chin Med Assoc 2003;66:433-5.
- Chang SC, Chen PK, Chen YR, Chang CN. *Treatment of frontal sinus osteoma using a craniofacial approach*. Ann Plast Surg 1997;38:455-9.
- Fobe LP, Melo EC, Cannone LF, Fobe JL. *Surgery of frontal sinus osteoma*. Arq Neuropsiquiatr 2002;60:101-5.
- Schick B, Steigerwald C, El Rahman El Tahan A, Draf W. *The role of endonasal surgery in the management of frontoethmoidal osteomas*. Rhinology 2001;39:66-70.
- Koivunen P, Lopponen H, Fors AP, Jokinen K. *The growth rate of osteomas of the paranasal sinuses*. Clin Otolaryngol 1997;22:111-4.

- 14 Namdar I, Eldestein DR, Huo J, Lazar A, Killmelmán CP, Soletic R. *Management of osteomas of the paranasal sinuses*. Am J Rhinol 1998;12:393-8.
- 15 Rappaport JM, Attia EI. *Pneumocephalus in frontal sinus osteoma. A case report*. J Otolaryngol 1994;23:6.
- 16 Huang HM, Liu CM, Lin KN, Chen HT. *Giant ethmoid osteoma with orbital extension, a nasoendoscopic approach using an intranasal drill*. Laryngoscope 2001;111:430-2.
- 17 Oostvogel CW, Hüttenbrink KB. *Pathogenesis of osteoma of the skull*. Laryngorhinootologie 1991;70:87-9.
- 18 Savic DL, Djeric DR. *Indications for the surgical treatment of osteomas of the frontal and ethmoid sinuses*. Clin Otolaryngol 1990;15:397-404.
- 19 Reiss M, Hüttenbrink KB. *Endoscopic removal of osteoma of the paranasal sinuses*. HNO 1997;45:233-6.
- 20 Udovicki J, Milosevic D, Dubljevic L. *Giant osteomas of the paranasal sinuses*. Med Pregl 1991;44:467-70.
- 21 Coste A, Chevalier E, Beautru R, Abd Alsamad I, Salvan D, Paynege R. *Osteoma of the naso-sinusal cavities. Surgical indications and role of endonasal endoscopic surgery*. Ann Otolaryngol Chir Cervicofac 1996;113:197-201.

■ Received: February 25, 2004  
Accepted July 14, 2004

■ Address for correspondence: Dr. B. Capolunghi, Presidio Ospedaliero Iseo, via Giardini Garibaldi 7, 25049 Iseo (Brescia), Italy. Fax +39 030 9887364. E-mail: basilio@tiscali.it